

## PennHIP Report

Referring Veterinarian: Dr Joshua Schulz	Clinic Name: Steamboat Animal Hospital
Email: steamboatanimalhospital@hotmail.com	Clinic Address: 6531 Sexton Drive NW Olympia, WA 98502
	Phone:
	Fax: (360) 866-9669

## Patient Information

Client: Hoekema, Cinnamon	Tattoo Num:
Patient Name: Meiko	Patient ID: 118579
Reg. Name: Hoekema Homestead Meiko Kai	Registration Num: SS25613006
PennHIP Num: 187744	Microchip Num: 956000013941761
Species: Canine	Breed: GOLDEN RETRIEVER
Date of Birth: 12 Mar 2021	Age: 25 months
Sex: Female	Weight: 67.1 lbs/30.4 kgs
Date of Study: 16 Apr 2023	Date Submitted: 17 Apr 2023
Date of Report: 18 Apr 2023	

## Findings

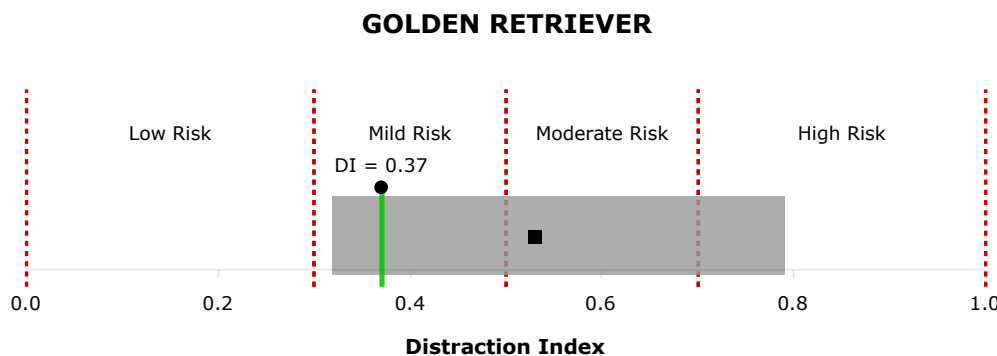
Distraction Index (DI): Right DI = 0.37, Left DI = 0.36.  
 Osteoarthritis (OA): **No radiographic evidence of OA for either hip.**  
 Cavitation/Other Findings: No cavitation present.

## Interpretation

Distraction Index (DI): The laxity ranking is based on the hip with the greater laxity (larger DI). In this case the DI used is 0.37.

OA Risk Category: The DI is between 0.31 and 0.49. This patient is at mild risk for hip OA.

Distraction Index Chart:



**BREED STATISTICS:** This interpretation is based on a cross-section of 25429 canine patients of the GOLDEN RETRIEVER breed in the AIS PennHIP database. The gray strip represents the central 90% range of DIs (0.32 - 0.79) for the breed. The breed average DI is 0.53 (solid square). The patient DI is the solid circle (0.37).

**SUMMARY:** The degree of laxity (DI = 0.37) falls within the central 90% range of DIs for the breed. This amount of hip laxity places the hip at a mild risk to develop hip OA. **No radiographic evidence of OA for either hip.**