

### PennHIP Report

Referring Veterinarian: Dr Joshua Schulz	Clinic Name: Steamboat Animal Hospital
Email: steamboatanimalhospital@hotmail.com	Clinic Address: 6531 Sexton Drive NW Olympia, WA 98502
	Phone: (360) 866-6101
	Fax: (360) 866-9669

### Patient Information

Client: Hoekema, Cinnamon	Tattoo Num:
Patient Name: Isla	Patient ID: 117552
Reg. Name: Moonlit Acres Hoekema Homestead Isla Nae	Registration Num: 5S33163001
PennHIP Num: 184385	Microchip Num: 956000014291459
Species: Canine	Breed: GOLDEN RETRIEVER
Date of Birth: 28 Jan 2022	Age: 12 months
Sex: Female	Weight: 60.6 lbs/27.5 kgs
Date of Study: 29 Jan 2023	Date Submitted: 29 Jan 2023
Date of Report: 30 Jan 2023	

### Findings

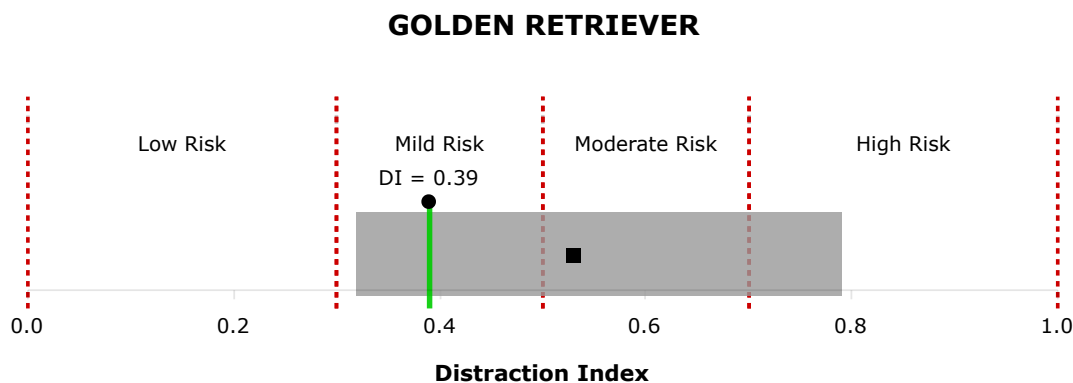
Distraction Index (DI): Right DI = 0.36, Left DI = 0.39.
Osteoarthritis (OA): <b>No radiographic evidence of OA for either hip.</b>
Cavitation/Other Findings: No cavitation present.

### Interpretation

Distraction Index (DI): The laxity ranking is based on the hip with the greater laxity (larger DI). In this case the DI used is 0.39.

OA Risk Category: The DI is between 0.31 and 0.49. This patient is at mild risk for hip OA.

Distraction Index Chart:



**BREED STATISTICS:** This interpretation is based on a cross-section of 25074 canine patients of the GOLDEN RETRIEVER breed in the AIS PennHIP database. The gray strip represents the central 90% range of DIs (0.32 - 0.79) for the breed. The breed average DI is 0.53 (solid square). The patient DI is the solid circle (0.39).

**SUMMARY:** The degree of laxity (DI = 0.39) falls within the central 90% range of DIs for the breed. This amount of hip laxity places the hip at a mild risk to develop hip OA. **No radiographic evidence of OA for either hip.**

